

Large goitre causing difficult intubation and failure to intubate using the intubating laryngeal mask airway: lessons for next time

H. G. WAKELING, A. ODY AND A. BALL

Summary

A 63-yr-old woman was anaesthetized for sub-total thyroidectomy. The thyroid gland was large, deviating the trachea to the right and causing 30% tracheal narrowing at the level of the suprasternal notch. Mask ventilation was easy but laryngoscopy was Cormack and Lehane grade 3. Despite being able to see the tip of the epiglottis, tracheal intubation was impossible. An intubating laryngeal mask was inserted and although the airway was clear and ventilation easy, it was not possible to intubate the trachea either blindly or with the fiberoptic bronchoscope. Tracheal intubation was eventually achieved using a 6.5-mm cuffed oral tracheal tube via a size 4 laryngeal mask under fiberoptic control. We describe the case in detail and discuss the use of the intubating laryngeal mask, its potential limitations and how to optimize its use in similar circumstances. (*Br. J. Anaesth.* 1998; **81**: 979–981).

Keywords: intubation tracheal; intubation tracheal, complications; equipment, masks anaesthesia

Difficulty with intubation may be caused by an enlarged thyroid gland producing tracheal deviation or compression, or both. The laryngeal mask airway has been recognized as a useful adjunct during difficult intubation. It appears in the American Society of Anesthesiologists' difficult airway algorithm, both as an emergency airway and the conduit of choice for the fiberoptic bronchoscope.¹ The intubating laryngeal mask airway (ILMA, Fastrach, Intavent, UK) recently became available. It is a laryngeal mask airway which has been adapted extensively to enable blind intubation of the trachea using an especially modified tracheal tube.² Brian and colleagues found this device to be useful for difficult intubation; easy ILMA ventilation and reliable tracheal intubation were achieved in a group of patients with known or predicted difficult intubation.³

We describe the airway management of a patient with a large goitre with particular emphasis on the use and potential limitations of the ILMA, with suggestions for optimizing ILMA technique.

Case report

A 63-yr-old retired nurse presented for thyroidectomy with a thyroid goitre of approximately 30 yr. She was euthyroid after treatment with propyl-

thiouracil. Past medical history included hypertension and palpitations when she was hyperthyroid. Medication included propranolol LA 160 mg daily and propylthiouracil 150 mg bid. She was allergic to tetracycline. She had undergone general anaesthesia uneventfully on three previous occasions. She had no stridor, hoarseness or difficulty breathing and was not a smoker. There was no history of gastro-oesophageal reflux.

Airway assessment revealed prominent incisor teeth and some crowned molars. Her mouth opened well and she had a Mallampati grade I upper airway. She had somewhat restricted neck extension but the trachea did not appear to be clinically deviated. A thoracic inlet x-ray showed tracheal deviation to the right, maximal just above the suprasternal notch, with approximately 30% narrowing of the trachea in its anteroposterior and transverse diameters at this point (fig. 1).

Cardiorespiratory assessment was normal with a slow regular heart rate of 56 beat min⁻¹ and arterial pressure of 170/80 mm Hg. Heart sounds were normal. There was no stridor. Chest expansion and breath sounds were normal. Full blood count, urea and electrolyte concentrations, and thyroid function tests were normal. She was premedicated with temazepam 20 mg and metoclopramide 10 mg orally.

A 16-gauge i.v. cannula was inserted into the left forearm and an infusion of Hartmann's solution commenced. Full non-invasive monitoring was used, including ECG, arterial pressure, oxygen saturation, inspired oxygen and end-tidal carbon dioxide before induction of anaesthesia. Previous discussion with the surgeon had excluded the need to stimulate the recurrent laryngeal nerve. Anaesthesia was induced with fentanyl 200 µg and thiopental (thiopentone) 400 mg. Mask ventilation was easy and vecuronium 8 mg was given to facilitate intubation. Anaesthesia was maintained with 1% isoflurane and 50% nitrous oxide in oxygen. The patient's head was placed on two pillows and the neck extended as far as the restriction allowed. Direct laryngoscopy using a size 3 MacIntosh blade revealed only the tip of the epiglottis. It was not possible to pass a gum-elastic bougie into the trachea. A size 4 McCoy laryngoscope was used but this did not improve the view. Between intubation attempts, the patient's lungs

HOWARD G. WAKELING*, BSC, MRCP, FRCA, ANDREW ODY, BSC, MB, ANDREW BALL, FRCA, Anaesthetic Department, Dorset County Hospital, Williams Avenue, Dorchester, Dorset DT1 2JY. Accepted for publication: July 28, 1998.

*Address for correspondence: 15 Emmett Road, Rownhams, Southampton SO16 8JB.

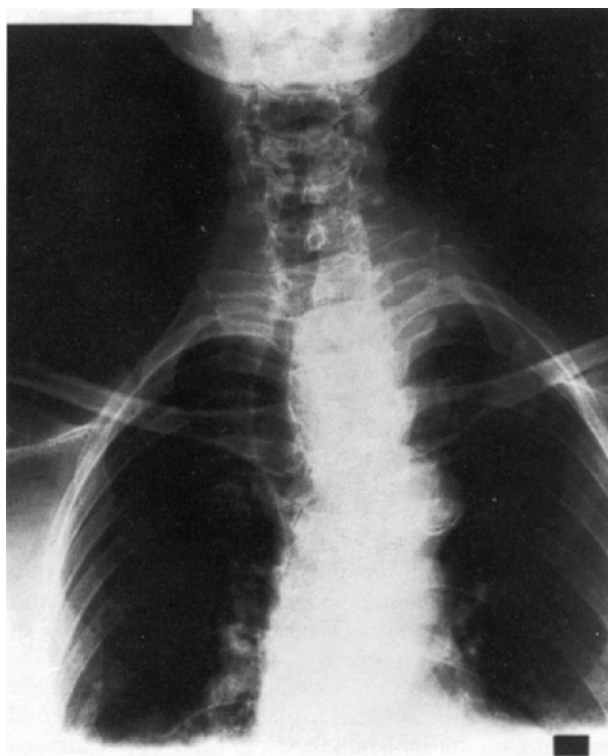


Figure 1 Thoracic inlet x-ray showing tracheal deviation caused by the large thyroid goitre.

were ventilated uneventfully using a face mask and adequate anaesthetic depth was maintained.

An ILMA size 4 was inserted easily into the hypopharynx and 30 ml of air were placed in the cuff. The breathing system was connected to the ILMA and easy, unobstructed manual ventilation established. The position of the ILMA was adjusted until an optimal seal was established. An 8-mm id ILMA tracheal tube was advanced down the ILMA in the position of optimal seal. The tracheal tube passed into the oesophagus on this and all other occasions without resistance. The position of the ILMA was adjusted several times. First, the mask was inserted further so that the first black line was at the level of the teeth. Second, the ILMA was withdrawn so that the fourth and then sixth lines were level with the teeth. Third, the ILMA was rotated gently to the right to compensate for the deviation of the trachea, and finally size 3 and then size 5 ILMA were tried, all without success. A fiberoptic bronchoscope loaded with a tracheal tube was then inserted via the ILMA. Passage of the fibrescope was extremely difficult and we were unable to see the larynx. This was partly because the epiglottic elevating bar (EEB) obscured the view and prevented the bronchoscope tip from passing sufficiently anterior. Despite trying to alter the position of the ILMA, it was impossible to see the laryngeal inlet.

A standard size 4 laryngeal mask was then inserted and ventilation established. It was eventually possible to see a swollen laryngeal opening using the fiberoptic bronchoscope via the LMA. The bronchoscope was inserted to reveal the tracheal bifurcation and a 6.5-mm id tracheal tube, already mounted, was rail-roaded over the scope. Tracheal intubation was confirmed by end-tidal carbon dioxide measurement and auscultation. The tracheal tube and LMA were

replaced with an 8-mm id tracheal tube over a gum-elastic bougie. Throughout this period, the patient remained stable with heart rate 60–70 beat min^{-1} and systolic arterial pressure 110–150 mm Hg. Oxygen saturation remained at 97–99% throughout.

Thyroidectomy was performed without complication. I.v. dexamethasone 10 mg was given to reduce glottic swelling. The patient was sedated and ventilated overnight in the intensive care unit. The following day, sedation and ventilation were weaned off. On deflating the tracheal tube cuff, an audible leak was heard and the tube was removed uneventfully. I.v. dexamethasone was continued for 24 h but there were no further airway difficulties.

Discussion

Patients with large goitres are considered to be more likely to present difficulty at intubation, particularly if the goitre has produced tracheal deviation or has retrosternal extension.⁴ In this case, there was radiological evidence of tracheal deviation which was asymptomatic. The patient had prominent incisor teeth and restricted neck extension. She was Mallampati grade I. Once the degree of intubation difficulty was established, several options were considered. Postponing the procedure and reducing the gland with radio-iodine was a possibility, but this can cause acute swelling and airway compromise. A laryngeal mask airway (LMA) was considered but there was a risk that tracheal intubation could be required urgently, as has been reported previously.⁵

Fiberoptic placement of the tracheal tube via a standard LMA was difficult because the larynx was deviated to the right and the laryngeal inlet had tipped forwards. To enter the laryngeal inlet, the bronchoscope had to be angled steeply anteriorly and to the right on emerging from the LMA, and then caudally when the posterior aspect of the laryngeal inlet had been passed.

The ILMA is a recently available device for blindly intubating the trachea.^{2,3,6} It consists of a modified LMA attached to a curved stainless steel tube. The curvature of the tube was developed using a series of sagittal magnetic resonance images (MRI) of the head and neck. The consequent tube curvature represents the best fit from the MRI series. The aperture bars have been replaced by the EEB which lifts the epiglottis up out of the way during tracheal tube placement. In addition, a 20° tracheal tube guiding ramp has been incorporated immediately behind the EEB to guide the tube more anteriorly.²

Interestingly, although tracheal intubation with the ILMA was not achieved in this case, ventilation via the ILMA was easy with all three sizes. In two recent ILMA studies, ventilation was easy in all 250 patients via the ILMA.^{3,6} This is important as we have not seen any reports of inability to ventilate in either our own series or in the literature. One of the preliminary studies clearly demonstrated a learning curve in gaining expertise with the use of the ILMA.⁶ This case report arose from our seventh use of the device. It represents one of only two failures in 56 uses to date.

There have been no reports of ILMA use in patients with distorted laryngeal anatomy. Although difficult intubation conditions have been described in two large preliminary studies^{3,6} and in a recent triple

case report,⁷ none has described an altered laryngeal position. The ILMA may have limited use in cases such as this where the laryngeal position has been altered significantly by disease.

However, there are some lessons that we have learnt from this case, subsequent cases and discussion with the inventor. First, the ILMA is for use with the head in the neutral position. We kept the head in the "sniffing" position throughout. This would have decreased the anterior angle of projection of the tracheal tube from the ILMA and directed it more towards the oesophagus. Second, with further experience we have found that lifting the ILMA handle such that the rim of the proximal end of the ILMA tube lies in the horizontal plane improves intubation success. This presumably increases the anterior projection angle, reducing the likelihood of oesophageal intubation.

We were unable to see the larynx using the fiberoptic bronchoscope via the ILMA. It was not possible to direct the bronchoscope anteriorly enough to reach the laryngeal inlet because of the EEB. The inventor suggested that this problem may be avoided by inserting the tracheal tube to the horizontal line (indicating that the tube tip lies at the EEB) and advancing it 1.5 cm to lift the EEB before inserting the bronchoscope. It may have been possible to locate the larynx fiberoptically with this approach as this was achieved through a standard LMA.

The inventor also suggested holding a second ILMA of the same size externally, exactly parallel to the inserted device. This permits estimation of the position of the EEB. The EEB should be cephalad to (i.e. above) but within 2 cm of the thyroid prominence, which approximates to the laryngeal inlet. By holding the second ILMA alongside, the inserted device can be manoeuvred to achieve the alignment described.

In summary, this case of difficult intubation arose from deviation of the laryngeal inlet anteriorly and laterally because of a large thyroid goitre. The ILMA provided a means of easy, unobstructed ventilation of the patient's lungs whichever size was used and despite the airway abnormalities. But failure to intubate with the device blind or with a fiberoptic bronchoscope occurred; inexperience may have contributed to this failure. However, this is the first case report of attempted ILMA use in the presence of abnormal laryngeal position. Further experience with the device in such cases is needed to determine if abnormal lower airway position represents a significant limitation to the usefulness of this device for tracheal intubation.

References

1. Benumof JL. Laryngeal mask airway and the ASA difficult airway algorithm. *Anesthesiology* 1996; **84**: 686–699.
2. Brain AIJ, Vergheze C, Addy EV, Kapila A. The intubating laryngeal mask. I: development of a new device for intubation of the trachea. *British Journal of Anaesthesia* 1997; **79**: 699–703.
3. Brian AIJ, Vergheze C, Addy EV, Kapila A, Brimacombe J. The intubating laryngeal mask. II: a preliminary clinical report of a new means of intubating the trachea. *British Journal of Anaesthesia* 1997; **79**: 704–709.
4. Sebel PS. Anaesthesia for thyroid and parathyroid disease. In: Nimmo WS, Rowbotham DJ, Smith G, eds. *Anaesthesia*. Oxford: Blackwell Scientific Publications, 1994.
5. Hobbiger HE, Allen JG, Greatorex RG, Denny NM. The laryngeal mask for thyroid and parathyroid surgery. *Anaesthesia* 1996; **51**: 972–974.
6. Kapila A, Addy EV, Vergheze C, Brain AIJ. The intubating laryngeal mask airway: an initial assessment of performance. *British Journal of Anaesthesia* 1997; **79**: 710–713.
7. Parr MJA, Gregory M, Baskett PJF. The intubating laryngeal mask. Use in failed and difficult intubation. *Anaesthesia* 1998; **53**: 343–348.