

REVIEW ARTICLE



Fifteen years of ultrasound guidance in regional anaesthesia: Part 2—Recent developments in block techniques

P. Marhofer^{1*}, W. Harrop-Griffiths², H. Willschke¹ and L. Kirchmair³

¹Department of Anaesthesia, Intensive Care Medicine, and Pain Therapy, Medical University of Vienna, Waehringer Guertel 18-20, A-1090 Vienna, Austria. ²Department of Anaesthesia, St Mary's Hospital, Praed Street, London W2 1NY, UK. ³Department of Anaesthesia, Intensive Care Medicine, and Pain Therapy, Medical University of Innsbruck, A-6020 Innsbruck, Austria

*Corresponding author. E-mail: peter.marhofer@meduniwien.ac.at

The use of ultrasound guidance for regional anaesthesia has gained enormous popularity in the last 10 yr. The first part of this review article provided information on safety, technical developments, economic aspects, education, advantages, needle guidance techniques, and future developments in ultrasound. The second part focuses on practical and technical details of individual ultrasound-guided nerve blocks in adults. We present a comprehensive review of the relevant literature of the last 5 yr with a commentary based on our own clinical experience in order to provide information relevant to patient management. Upper limb blocks, including interscalene, supra- and infraclavicular, and axillary approaches, are described and discussed. For the lower limb, psoas compartment, femoral, obturator, sciatic, and lateral cutaneous nerve blocks are described, as are some abdominal wall blocks. The potential role of ultrasound guidance for neuraxial block is addressed. The need for further large-scale studies of the role of ultrasound is emphasized.

Br J Anaesth 2010; 104: 673–83

Keywords: anaesthetic techniques, regional; equipment, ultrasound machines; nerve block

The use of ultrasound guidance for regional anaesthesia has gained enormous popularity in the last 10 yr. This second part of our review focuses on practical and technical details of individual ultrasound-guided nerve blocks in adults. We present a comprehensive review of the relevant literature of the last 5 yr with a commentary based on our own clinical experience in order to provide information relevant to patient management.

Upper limb

Although the structure and innervation of the arm, shoulder, and lateral clavicular area is complex, the superficial location of the brachial plexus, its branches, and the surrounding structures allow high-quality ultrasound images to be achieved, thereby making upper limb regional blocks highly amenable to ultrasound-guided techniques.

Interscalene approach

It is possible, using ultrasound, to identify the phrenic nerve on the surface of the anterior scalene muscle⁴⁰ where it is in close proximity to the phrenic nerve C₅ root

at the level of the cricoid cartilage. This close anatomical relationship explains the high incidence of ipsilateral phrenic nerve block after interscalene brachial plexus block, which can be of clinical significance in patients with lung disease.²⁵ It emphasizes the fact that the phrenic nerve may be at risk of damage during an interscalene brachial plexus block performed at the cricoid level.

An ultrasound-guided posterior approach to the brachial plexus using *Pippa's* technique has been described⁸⁵ and the feasibility of continuous brachial plexus block with this posterior approach demonstrated.^{3 48} The efficacy of this technique was also demonstrated in a randomized, placebo-controlled study of 32 patients undergoing shoulder surgery.⁴⁷ The proposed benefits of a continuous posterior brachial plexus block are avoidance of the external jugular vein, a greater distance between the catheter entry site and the surgical field, and a lower incidence of catheter migration.⁴⁷ Nevertheless, a posterior approach to the brachial plexus—often termed a cervical paravertebral block—also has potential disadvantages. The needle has to be advanced through the muscles of the neck for some distance on its way to the brachial plexus. This can be painful for the patient. The needle has to pass through the

middle scalene muscle, which contains two proximal branches of the brachial plexus: the long thoracic and dorsal scapular nerves. These nerves may therefore be injured by a needle approach that passes through the middle scalene muscle. Inserting the needle deep into the neck may make it difficult for novices to maintain full needle visibility when using an 'in-plane' technique in which the needle passes along the narrow ultrasound beam parallel to the probe head. If the needle is not well visualized, there is a risk that it may be inadvertently inserted towards the cervical spine. The lateral 'in-plane' approach to the interscalene brachial plexus also carries a theoretical risk of injuring the nerves lying within the middle scalene muscle, and needle advancement towards the midline when ultrasound visualization is poor can be hazardous.

In our opinion, an 'out-of-plane' approach using a needle entry point and direction of insertion similar to that used in the modified traditional lateral technique^{51 52} seems to be the most logical and safe technique. The brachial plexus is superficial in this location (Fig. 1), and the depth of needle insertion is much less when compared with the 'in-plane' and posterior approaches. Moreover, the needle can be advanced at a very shallow angle almost parallel to the nerves of the brachial plexus. In our experience, injection of local anaesthetic lateral, medial, and in close proximity to the nerve roots with this approach produces an excellent nerve block.³⁵ A common argument against an 'out-of-plane' approach is poor needle and needle tip visualization during the block. However, we believe that if the needle is advanced slowly and carefully while closely observing the movement of the tissues around the roots of the brachial plexus, this is a safe and effective technique. The insertion of a catheter is made easier by the use of this technique as the catheter is more likely to pass parallel to and alongside the nerves during placement.

Supraclavicular approach

Since the introduction of ultrasound guidance, supraclavicular brachial plexus block has seen resurgence in popularity and now replaces infraclavicular approaches in the practice of many clinicians. The supraclavicular region offers excellent imaging conditions because of the superficial location

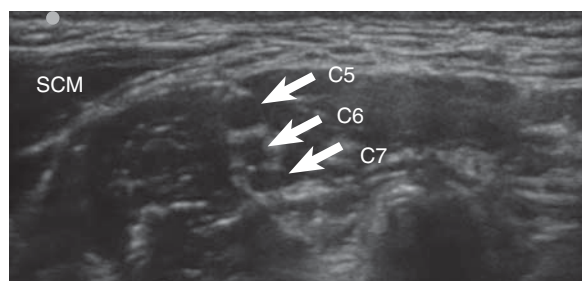


Fig 1 Ultrasound scan of the C₅₋₇ nerve roots at the level used for the interscalene approach. SCM, sternocleidomastoid muscle; C₅, C₆, C₇, cervical nerve roots.

of the brachial plexus and its surrounding structures: the subclavian artery, the pleura, and the first rib. As for the interscalene block, both 'in-plane' (Fig. 2) and 'out-of-plane' techniques are possible. Most regional anaesthetists use an 'in-plane' technique that seeks to minimize the chances of the needle hitting the artery or pleura. The optimal injection site has been described as being in the 'corner pocket', which is bordered by the first rib inferiorly, the subclavian artery medially, and the brachial plexus superiorly.⁷⁵ An alternative approach has been described in which a medio-lateral needle direction aims to avoid pleural puncture in cases in which the needle is poorly visible with ultrasound.¹⁷ A study of 510 consecutive patients assessed success rates and the incidence of complications with both techniques.⁶⁰ Side-effects and complications included symptomatic diaphragmatic paresis (1%), Horner's syndrome (1%), vascular puncture (0.4%), and transient neurological deficits (0.4%). No pneumothoraces were seen. There were no statistically significant differences in success rates or complication rates between the latero-medial and medio-lateral needle direction techniques. Therefore, no firm recommendations can be made about which technique should be used, so the needle direction used in an 'in-plane' technique in this area can be left to the anaesthetist's discretion. Most anaesthetists use high-frequency linear array transducers to provide optimal ultrasound images for brachial plexus blocks. In a recently published retrospective case series, the combined use of a low-frequency (5–8 MHz) curved array transducer and nerve stimulation was reviewed.^{81 82} Although success rates were equal to those reported in other publications on ultrasound-guided blocks,⁶⁰ the images presented did not match the quality of those produced by modern, high-frequency probes and equipment. We believe that ultrasound-guided brachial plexus blocks should be performed with the high-resolution images obtained with modern, high-frequency linear array transducers.

A dose-finding study²² of the minimum effective volume of local anaesthetic for an ultrasound-guided

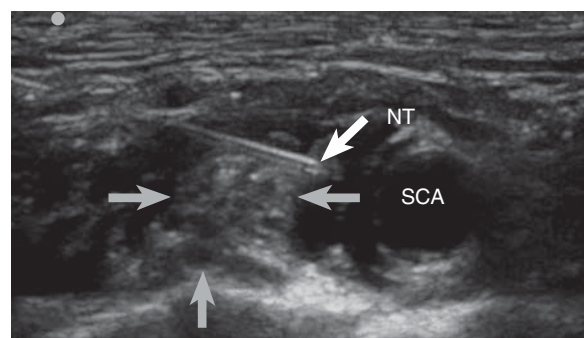


Fig 2 Ultrasound scan of the brachial plexus at the supraclavicular level using an 'in-plane' technique. The brachial plexus is labelled with grey arrows and lies directly above the cervical pleura. The hypoechoic area around the brachial plexus was created by the injection of 8 ml of local anaesthetic solution. NT, needle tip; SCA, subclavian artery.

supraclavicular brachial plexus block found a calculated minimum effective volume of 23 ml (of a 50:50 mixture of lidocaine 2% and bupivacaine 0.5%) and a calculated ED₉₅ of 42 ml. Higher volumes for supraclavicular block when compared with interscalene block can be explained by the anatomical conformation of the supraclavicular part of the brachial plexus, which has a significant amount of connective tissue both surrounding and within the plexus.⁵³ These volumes may be reduced as practitioners gain experience with this particular technique.

A number of published clinical cases and case series show the usefulness of ultrasound guidance in the management of complex cases^{21 28 61 71} or in avoiding serious complications.⁸⁴ The successful use of ultrasound-guided supraclavicular nerve blocks in an emergency setting has been reported.^{77 78} However, there is some evidence that in spite of the above-mentioned advantages, ultrasound-guided supraclavicular brachial plexus block may not be as effective as is assumed when a single injection into the 'corner pocket' is used. In a comparison of this technique with a triple injection around the axillary artery in the infraclavicular region,²⁷ similar onset times were found but surgical anaesthesia was of significantly higher quality in the infraclavicular group, with fewer additional interventions. On the basis of our clinical experience, two to three injections are necessary to achieve complete and rapid spread around and within the supraclavicular brachial plexus. A single injection into the 'corner pocket' results not uncommonly in partial block failure. Optimal imaging conditions and careful needle guidance have made this block our first choice for surgical procedures between the shoulder and the elbow.

For operations on the hand and forearm, infraclavicular or axillary brachial plexus blocks are arguably more appropriate because it is easier to produce a reliable spread of local anaesthetic around the median, ulnar, and musculocutaneous nerves. A comparison⁴¹ of ultrasound-guided supraclavicular and infraclavicular brachial plexus blocks in patients undergoing hand and forearm surgery, using multiple injections for both techniques, found the infraclavicular approach more effective in blocking the median and ulnar nerves. A limitation of this study was a heterogeneous group of operators with different levels of experience. However, in a previous study, both techniques were found to be equally effective in terms of onset times and success rates.⁴

Infraclavicular approach

Ultrasound-guided infraclavicular plexus block can be managed by means of an 'in-plane' parasagittal or 'out-of-plane' approach. Using the 'in-plane' technique (also termed the 'coracoid approach'), the arm is abducted to ~90°, thus limiting the technique's use in the management of upper limb fractures. We use a lateral infraclavicular approach (Fig. 3) with 'out-of-plane' needle guidance. With this technique, the arm is allowed to rest in a neutral

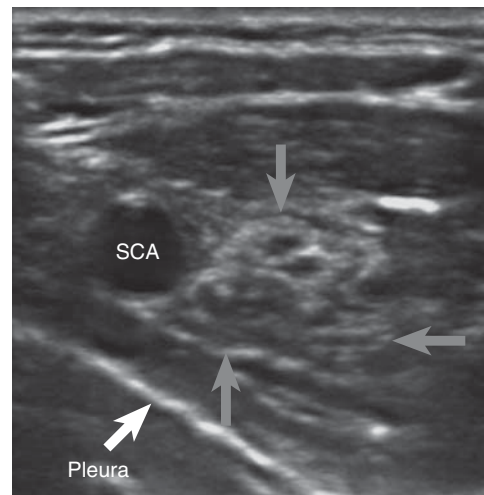


Fig 3 Ultrasound scan of the brachial plexus at the infraclavicular level below the pectoralis major and minor muscles. The three cords are labelled by grey arrows. SCA, subclavian artery.

position by the patient's side, and the needle distance from skin to plexus is at its shortest. However, both techniques are in regular clinical use and there is no evidence for advantages of one technique over the other. A complete and rapid onset of nerve block is achieved when the local anaesthetic is injected posterolateral to the artery, thus producing a U-shaped spread of fluid around the axillary artery.¹⁹ Visualization of the pattern of local anaesthetic spread after radial or median nerve stimulation and subsequent injection in the infraclavicular area found a positive radial nerve response resulted in a 100% block success rate with local anaesthetic injection posterior to the axillary artery.⁹ In contrast, a median nerve response resulted in local anaesthetic injection superficial to the artery and a lower success rate. Injection posterior to the artery has been described as producing the 'double bubble' sign.⁸⁰

Significant amounts of connective tissue surrounding and among the nerves of the brachial plexus are also seen at the infraclavicular region. A study of septa and their impact on local anaesthetic spread found that after injection with a lateral needle position, incomplete spread was noticed in 6 of 22 cases.⁵⁴ Limited local anaesthetic spread due to the presence of septa was found in four of these cases. It is a frequent finding that before injection posterior to the artery, a fascial click with subsequent rapid distribution of local anaesthetic around the artery is associated with a successful block.⁴³ A recent study showed no differences in terms of onset times and success rates when comparing single- and triple-injection techniques using a lateral parasagittal approach when the local anaesthetic is injected posterior to the axillary artery.¹⁸

Axillary approach

The use of ultrasonography has also revolutionized the performance and success rates of axillary brachial plexus

block. Detailed anatomical knowledge, especially about the frequent variations in the organization of the axillary brachial plexus, is the key to clinical success. The anatomical variability of the axillary brachial plexus was recently highlighted.¹⁵ It is now widely accepted that all four nerves (median, ulnar, radial, and musculocutaneous) should be blocked by separate injections around each nerve.²⁹ This will provide excellent surgical anaesthesia and tourniquet tolerance for procedures on the hand and forearm.^{14 69} It has been demonstrated that each nerve is surrounded by connective tissue, thus being effectively located in its own tissue compartment.⁵ In a series of 10 axillary plexus blocks, tissue barriers between the nerves were shown with three-dimensional (3D) ultrasonography.¹⁶ Whether 3D ultrasound will ever find its place in routine clinical practice is a matter for debate.

In our routine clinical practice, local anaesthetic is injected around each of the four nerves separately.⁷³ In some instances, the radial nerve is difficult to visualize (Fig. 4) because of its close proximity to the brachial artery, and subsequent misinterpretation of the images can decrease success rates.¹⁴ Nevertheless, the radial nerve shows a very consistent location between the 4 o'clock and 6 o'clock positions in relation to the brachial artery.¹⁵ After injection of a small volume of local anaesthetic, the radial nerve reliably shows a significant increase in visibility and can therefore be easily identified and blocked.

Needle guidance for axillary brachial plexus block can be 'out of plane'⁶⁹ or 'in plane'.^{14 73} and we have found both to be highly effective. Nevertheless, in terms of safety, the 'in-plane' technique offers better needle visualization, which is particularly important during injections close to the nerves. Recently, intravascular injection has been reported.^{65 91} The incidence of this complication can be minimized by pressing only lightly with the ultrasound probe before injection and thus not compressing the veins,

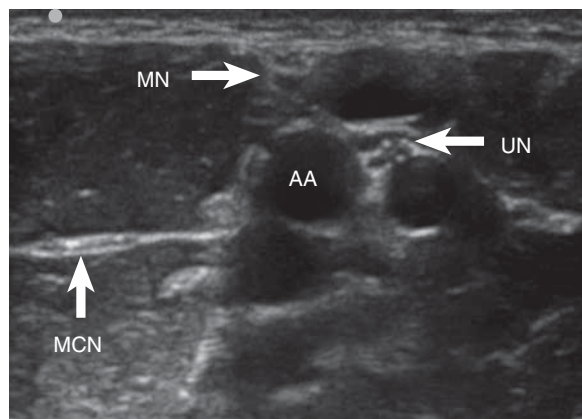


Fig 4 Ultrasound scan of the median (MN), ulnar (UN), and musculocutaneous (MCN) nerves at the axillary level. The musculocutaneous nerve lies between the short head of the biceps muscle (above) and coracobrachialis muscle (below). The radial nerve is not shown with this scanning head position. AA, axillary artery.

and aspiration tests are more likely to be positive if the needle is in a vessel.

Lower limb

In contrast to the upper limb, the sono-anatomy of the leg is straightforward. However, in spite of substantial technical advances in ultrasound probes and image processing in the last few years, ultrasound examination of the lower limb can still be very challenging because of the amount of muscle and fat that can surround nerves.⁶⁶

Psoas compartment block

The use of ultrasound guidance for posterior lumbar plexus block, or 'psoas compartment block', was one of the first to be described. The well-recognized advantage of a posterior approach to lumbar plexus is a reliable block of the femoral nerve, obturator nerve, and lateral cutaneous nerve of the thigh with a single injection. Originally, an 'in-plane' technique was described based on the identification of the psoas major muscle in the transverse plane at the L₃₋₅ level. In this area, the lumbar plexus, although deep, can be visualized using ultrasound. However, the use of nerve stimulation in addition to ultrasound imaging is still recommended to confirm the correct needle placement. This combined technique is still our standard practice when performing lumbar plexus block in the management of difficult cases such as hip fractures in elderly patients with significant co-morbidities. A slightly different technique based on imaging of the psoas major muscle in a paravertebral longitudinal view and advancing the needle 'in plane' in a cephalad direction has been described.³⁶ One concern about this technique is that systemic local anaesthetic toxicity might occur because of the rapid absorption of large volumes or because of inadvertent injection into one of the large paravertebral blood vessels. Bilateral spread is also a known side-effect of posterior lumbar plexus block. Interestingly, since we have introduced ultrasound guidance for these blocks into our practice, we have seen no instances of bilateral epidural spread.

In summary, posterior lumbar plexus block represents one of the most challenging techniques in terms of both ultrasound imaging and needle guidance. It should therefore only be performed or supervised by experienced clinicians. The clinical value of this technique has not yet been studied systematically.

Femoral nerve block

In femoral nerve block an 'out-of-plane' approach is used commonly. This is our routine clinical practice because skin-to-nerve needle distance is short and catheter placement is easy to achieve because the needle passes parallel to the long axis of the femoral nerve. Some clinicians use

an 'in-plane' approach and guide the needle in a latero-medial direction⁵⁶ (Fig. 5). An oblique needle–probe alignment for catheter placement has been suggested to reach the posterior surface of the femoral nerve.²⁶ Occasionally, clear delineation of the femoral nerve may be difficult in some cases because of its position between the iliopsoas muscle and fascia. In order to avoid nerve damage in these cases, we recommend approaching the nerve as laterally as possible where it is more visible in cross-section when compared with an approach medial to the nerve.

An ultrasound-guided fascia iliaca block was found to be superior when compared with the traditional approach using 'loss of resistance' to identify the correct plane.²⁰ This technique requires higher volumes of local anaesthetic than the femoral nerve block but seems to be a useful alternative in cases of poor imaging conditions. In the vast majority of cases, we prefer the injection of smaller volumes of local anaesthetic close to the femoral nerve.

Saphenous nerve block

The indication for saphenous nerve block combined with a distal sciatic nerve block is surgery to the foot and ankle. An infrapatellar branch block can be used for analgesia after knee arthroscopy.

The saphenous nerve is a sensory terminal branch of the femoral nerve. It passes together with the femoral artery underneath the sartorius muscle where it can be accessed by means of a trans-sartorial approach in the middle third of the thigh. Subsequently, the femoral artery passes medially to enter the adductor canal and gives off the descending genicular artery, which passes distally together with the saphenous nerve. Ultrasound-guided block of the saphenous nerve is also possible at this location with the sartorius muscle as a major landmark (Fig. 6).⁴² An ultrasound-guided block of the infrapatellar branch, at the level at which it separates from the saphenous nerve, proved effective in a small group of volunteers.⁴⁴ We use a trans-sartorial approach using an 'in-plane' technique.

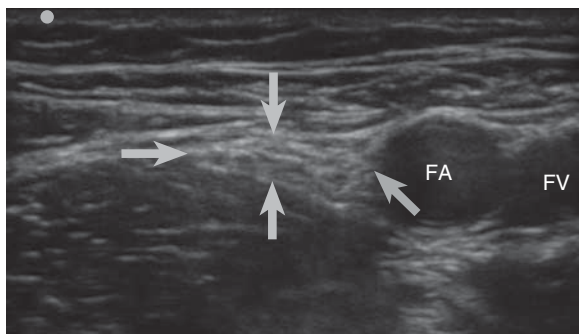


Fig 5 Ultrasound scan of the femoral nerve (labelled by the grey arrows) slightly distal to the inguinal ligament. FA, femoral artery; FV, femoral vein.

Obturator nerve block

There is an increasing interest in obturator nerve block for endoscopic urological procedures and the management of pain associated with major knee surgery. It has been shown that the obturator nerve provides a variable sensory supply to the medial aspect of the thigh and parts of the knee joint, and gives off branches to the hip joint as well. The feasibility of ultrasound imaging of the obturator nerve has been confirmed with nerve stimulation.⁷⁶ In a series of 22 patients, an 'out-of-plane' approach was used for the anterior branch of the obturator nerve, which is assumed to carry sensory fibres to the limb.³³ The anterior branch is shown as a flat, hyperechoic structure between the pectineus, adductor longus, and adductor brevis muscles (Fig. 7). In spite of these encouraging results, the detailed description of the underlying anatomy needs some refinement since the obturator nerve shows a considerable degree of variability at this level.^{2 67} Recently, a proximal approach to the obturator nerve before its bifurcation was used successfully in a small series of chronic pain patients with hip, knee pain, and obturator neuralgia.¹

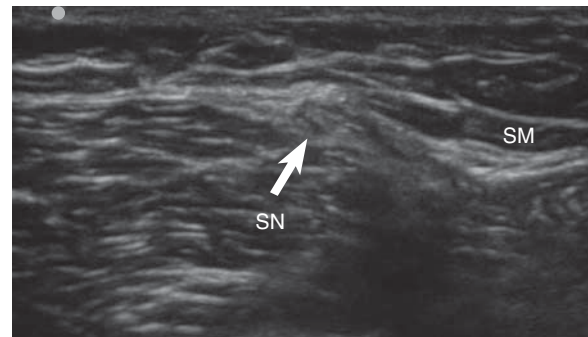


Fig 6 Ultrasound scan of the saphenous nerve (SN) below the sartorius muscle (SM).

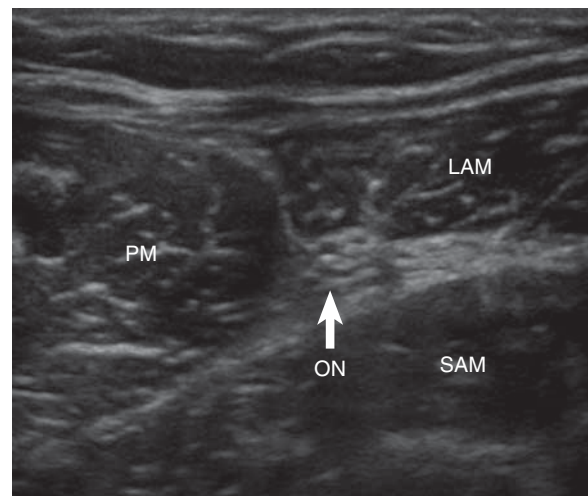


Fig 7 The anterior branch of the obturator nerve (ON) between the pectineus (PM), long adductor (LAM), and short adductor (SAM) muscles.

A completely different method using interfascial injections without the use of nerve stimulation and with an 'in-plane' technique has been described.⁷² Local anaesthetic solution (5 ml) was injected in between the pectineus and adductor brevis muscles, and between the adductor brevis and magnus muscles, to surround both branches of the obturator nerve. In our practice, we identify the anterior branch of the obturator nerve between the pectineus and adductor brevis muscles, and use an 'in-plane' approach to inject a volume of 5–10 ml of local anaesthetic close to it.

Lateral cutaneous nerve of the thigh block

Using modern ultrasound equipment, even the smallest nerves can be visualized successfully. Block of the lateral cutaneous nerve of the thigh near the anterior superior iliac spine is useful when seeking complete anaesthesia of the thigh. It is also a valuable tool in the diagnosis and treatment of chronic pain in this area, and an ultrasound-guided technique has been used in a series of 10 patients.³⁴ A case report demonstrated the successful management of meralgia paraesthetica with an ultrasound-guided lateral cutaneous nerve of the thigh block.⁸³ This early clinical experience was supported by an anatomical study that showed the reliability of an ultrasound-guided approach below the anterior superior iliac spine.⁵⁵ A highly selective technique using ultrasound produced successful blocks with only 0.3 ml of lidocaine.¹⁰

Sciatic nerve blocks

Sciatic nerve blocks can be performed using a number of techniques and approaches. In general, the nerve can be blocked at any site in its course, provided good ultrasound images can be achieved. The sciatic nerve can be visualized by ultrasonography from the gluteal region to the popliteal fossa.^{8 11 13 37 68} However, imaging of the sciatic nerve can be challenging for a number of reasons. The large amounts of muscle and fat surrounding the nerve can impair ultrasound visualization. Curved array probes operating at lower frequencies (5–8 MHz) provide better images, in particular for transgluteal and anterior approaches. The anisotropic behaviour of the sciatic nerve is a frequent cause of poor nerve visibility.

We use the *transgluteal approach* to block the sciatic nerve proximally and combine it with a posterior lumbar plexus block for the management of hip fractures in the elderly with significant heart disease such as severe aortic stenosis. The sciatic nerve gives off branches to the posterior aspect of the hip joint. The *anterior approach* to the sciatic nerve is a useful alternative in patients who are difficult to position. For reliable ultrasound imaging, the thigh has to be externally rotated by about 30°–45°, which limits its use in some patients with lower limb trauma. For most patients, the *subgluteal approach* is our method of choice, as it combines optimal imaging conditions and

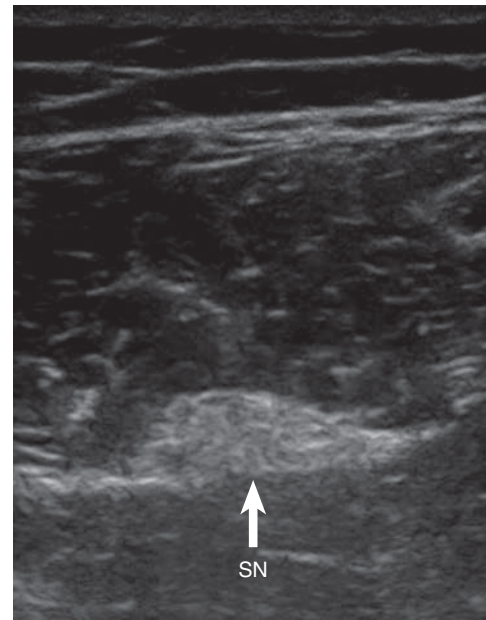


Fig 8 The sciatic nerve (SN) in the subgluteal region.

simple access to the sciatic nerve (Fig. 8). Knee surgery, vascular surgery, and leg amputations are the commonest indications for this block, which can be performed with the patient lying supine or in the lateral position.

More distal approaches to the sciatic nerve can be used for surgical procedures on the ankle and foot. Distal sciatic nerve blocks can be achieved using a lateral approach, advancing the needle 'in plane', or a posterior approach with 'out-of-plane' needle guidance. Initially, we recommend the performance of all distal sciatic approaches with the patient in the prone position if possible. Visualization of the sciatic nerve is better and needle guidance is easier with the patient in this position.

Peripheral nerve blocks

Although a *posterior tibial nerve* block at the ankle seems to be one of the easiest techniques, results are sometimes disappointing. Ultrasound-guided posterior tibial nerve block at the medial malleolus was shown to be significantly superior to the traditional landmark-based technique in a small group of volunteers, with an overall success rate of about 70%.^{63 74} Ultrasound-guided sural nerve block at the ankle using the lesser saphenous vein as a major landmark has been described.⁶⁴

Trunk blocks

Ilioinguinal/iliohypogastric blocks are described in children^{87 89} and adults.²³ The initial description of ultrasound-guided ilioinguinal–iliohypogastric blocks was a randomized and comparative study in 100 children⁸⁹ and showed a success rate of 96% in the ultrasound group when compared with a 74% success rate in the 'fascial

click' group. The ultrasound-guided technique is easy to perform with an in-plane or out-of-plane technique. Identification of the ilioinguinal and iliohypogastric nerves is usually simple at the level of the anterior superior iliac spine between the internal oblique and transversus abdominis muscles (Fig. 9). In a subsequent study using a volume reduction protocol, the same authors determined a local anaesthetic volume of 0.075 ml kg^{-1} as being sufficient.⁸⁷ The ilioinguinal and iliohypogastric nerves can be blocked selectively.²³

The use of a *TAP block* is growing rapidly. It has been shown that the technique provides effective analgesia after a wide range of abdominal operations.^{12 49 50 59} The concept behind this approach is to inject local anaesthetic solution into the plane between the internal oblique and transversus abdominis muscles to block intercostal nerves T₇–T₁₂, the ilioinguinal and iliohypogastric nerves, and the lateral cutaneous branches of the L_{1–3} dorsal rami. Initially, a blind 'two-pop' loss of resistance technique was described for the injection of local anaesthetic into the abdominal wall at the lumbar triangle—the Triangle of Petit.⁵⁰ A case report of liver trauma showed the potential dangers of blind injections into the abdominal wall.⁵⁸

The use of ultrasound-guided TAP blocks in patients undergoing laparoscopic gynaecological surgery has been reported.⁷⁰ A subcostal oblique ultrasound-guided TAP block with a needle insertion point near the xyphoid process³² and ultrasound-guided TAP blocks above the iliac crest⁸⁶ have been described.

Ultrasound imaging of the abdominal wall in the mid-axillary line reveals three muscular layers: the external oblique, the internal oblique, and the transversus abdominis muscles (Fig. 10). The needle is guided by an 'in-plane' technique and passes into the plane between the latter two muscles, allowing local anaesthetic solution to be injected into the TAP. A cadaver study showed that ultrasound-guided dye injection above the iliac crest mainly involves the T₁₀–L₁ dermatomes,⁷⁹ and a multiple

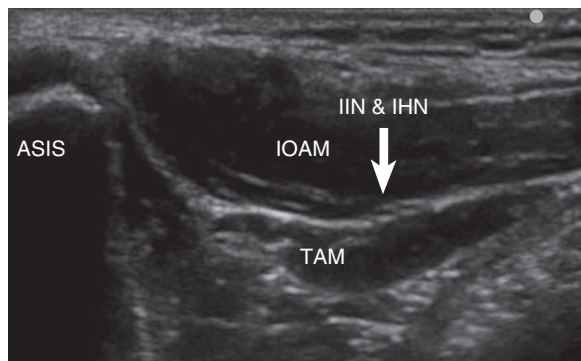


Fig 9 Transverse ultrasound scan of the ilioinguinal and iliohypogastric nerves (IIN and IHN) medial to the anterior superior iliac spine (ASIS). IOAM, internal oblique abdominal muscle; TAM, transversus abdominis muscle. Only the aponeurosis of the external oblique abdominal muscle above the IOAM is visible in this scan at that level.

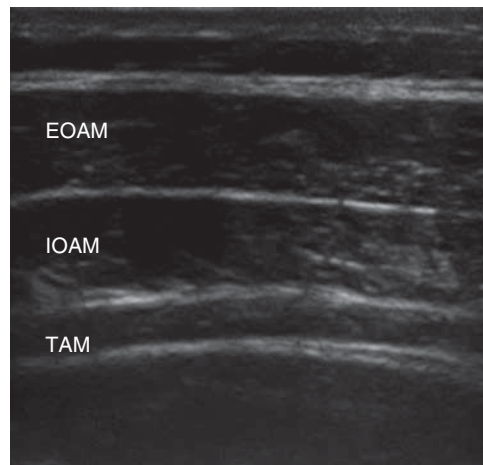


Fig 10 The lateral abdominal wall with the external oblique (EOAM), internal oblique (IOAM), and transversus abdominis muscles (TAM). The local anaesthetic needs to be injected between the inner two muscle layers.

injection technique to extend local anaesthetic spread has been proposed.⁶

Recently, several authors have been able to demonstrate the analgesic efficacy of ultrasound-guided TAP blocks in a number of different clinical settings.^{7 24 57} To provide analgesia with a TAP block, total volumes of local anaesthetic of 30–40 ml have to be injected. High plasma concentrations have been measured 15 min after TAP block in 12 patients.³⁹ This raises concerns about the possibility of systemic toxicity and a possible systemic analgesic effect of the injected local anaesthetic resulting from the high plasma levels.

TAP block represents an interesting and effective regional anaesthetic technique for the provision of pain relief after abdominal surgery. Future studies should define its risks and benefits, and compare them with epidural techniques, which can be considered the 'gold standard' for the provision of abdominal analgesia.

Neuraxial techniques

The use of *ultrasound-guided neuraxial techniques* in adults is controversial. The results of the study⁴⁶ which observed a decreased ultrasound visibility of neuraxial anatomical structures with increasing weight and age in children can be translated and extended to adults, in whom high-quality images of neuraxial structures are hard to achieve. It is a harsh anatomical fact that bones interfere with ultrasound, resulting in greatly impaired visibility of relevant neuraxial anatomical structures.

An in-plane technique for epidural injection in 15 adults has been described³⁸ using a technique similar to that described in children,^{88 90} and the authors were able to identify the epidural space in 14 of 15 cases. Anterior displacement of the posterior dura and the spread of local

anaesthetic could be observed in eight of 15 cases. In common with their description of this technique for children, they used a combination of ultrasound and the conventional loss-of-resistance technique.³⁸ There are currently no comparative studies of the use of ultrasound-guided epidural injection or catheter placement in adults. Imaging of the epidural space in adults is at the limits of current technology and routine adoption of ultrasound-guided techniques must await further technical developments.

Paravertebral blocks are much more promising for ultrasound-guided techniques because of better visualization with ultrasound. The paravertebral space is located lateral to the vertebral column and appears as a wedge-shaped space. The anterolateral boundary is formed by the parietal pleura, and the medial boundary is formed by the posterolateral aspect of the vertebral body, the intervertebral disc, the intervertebral foramen and its contents, and the superior costotransverse ligament, which extends from the lower border of the transverse process above to the upper border of the transverse process below, forming the posterior wall of the paravertebral space. The apex of the paravertebral space is continuous with the intercostal space lateral to the tips of the transverse processes. The endothoracic fascia, which is interposed between the parietal pleura and the superior costotransverse ligament, divides the paravertebral space into two compartments: the anterior extrapleural and the posterior subendothoracic paravertebral compartments. The thoracic paravertebral space contains the intercostal spinal nerves, the dorsal rami, the rami communicantes, the sympathetic chain, intercostal vessels, and fatty tissue. The intercostal nerves and vessels are located behind the endothoracic fascia, whereas the sympathetic trunk is located anterior to it in the paravertebral space (Fig. 11). In an early study, ultrasound was used to identify the pleura lateral to the transverse process at the T₄ level to confirm the maximum

depth of needle insertion.⁶² Subsequently, a different technique was suggested,³⁰ but the authors were not able to identify the position of the needle. Recently, the same authors have proposed ultrasound-guided paravertebral blocks for breast surgery.³¹

More detailed information from a human cadaver study describes the relevant ultrasound anatomy.⁴⁵ Reliable identification of the superior costotransverse ligament and the paravertebral space was possible in 10 cadavers, resulting in the accurate administration of fluid. Catheter placement is associated with a high failure rate, with the tip of the catheter often found in the epidural, mediastinal, or pleural space. Once the paravertebral space is correctly identified lateral to the transverse process and below the superior costotransverse ligament, the needle can be introduced with an out-of-plane needle guidance technique. Depending upon the indication for the block, a puncture at one or two levels can be performed.

Summary

Ultrasound-guided regional anaesthetic techniques are now fully integrated into the everyday clinical practice of a large number of anaesthetists. Technological advances in the design of ultrasound equipment have allowed clear visualization of the majority of nerves. Notwithstanding this substantial growth in interest and in clinical practice, large outcome studies are still lacking and should be the focus of efforts in the next few years. However, our experience of 15 yr of the regular and routine use of ultrasound-guided blocks has shown that these techniques are both highly effective and safe. We can only hope that the increased interest in ultrasound will produce an increasing number of high-quality studies that will further develop both the science and art of regional anaesthesia.

Conflict of interest

P.M. has received funding to defray the expenses of attendance at conferences from SonoSite Ltd.

References

- 1 Akkaya T, Ozturk E, Comert A, et al. Ultrasound-guided obturator nerve block: a sonoanatomic study of a new methodologic approach. *Anesth Analg* 2009; **108**: 1037–41
- 2 Anagnostopoulou S, Kostopanagiotou G, Paraskeuopoulos T, Alevizou A, Saranteas T. Obturator nerve block: from anatomy to ultrasound guidance. *Anesth Analg* 2008; **106**: 350–1 (author reply)
- 3 Antonakakis JG, Sites BD, Shiffrin J. Ultrasound-guided posterior approach for the placement of a continuous interscalene catheter. *Reg Anesth Pain Med* 2009; **34**: 64–8
- 4 Arcand G, Williams SR, Chouinard P, et al. Ultrasound-guided infraclavicular versus supraclavicular block. *Anesth Analg* 2005; **101**: 886–90

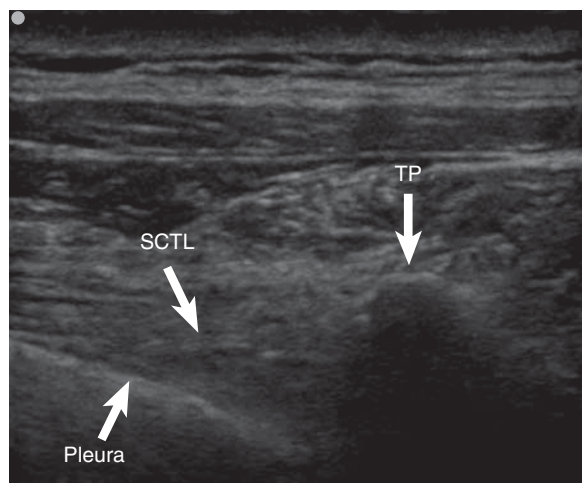


Fig 11 The paravertebral space between the transverse process (TP), the superior costotransverse ligament (SCTL), and the parietal pleura.

- 5 Ay S, Akinci M, Sayin M, Bektas U, Tekdemir I, Elhan A. The axillary sheath and single-injection axillary block. *Clin Anat* 2007; **20**: 57–63
- 6 Barrington MJ, Ivanusic JJ, Rozen WM, Hebbard P. Spread of injectate after ultrasound-guided subcostal transversus abdominis plane block: a cadaveric study. *Anaesthesia* 2009; **64**: 745–50
- 7 Belavy D, Cowlshaw PJ, Howes M, Phillips F. Ultrasound-guided transversus abdominis plane block for analgesia after Caesarean delivery. *Br J Anaesth* 2009; **103**: 726–30
- 8 Ben-Ari AY, Joshi R, Uskova A, Chelly JE. Ultrasound localization of the sacral plexus using a parasacral approach. *Anesth Analg* 2009; **108**: 1977–80
- 9 Bloc S, Garnier T, Komly B, et al. Spread of injectate associated with radial or median nerve-type motor response during infraclavicular brachial-plexus block: an ultrasound evaluation. *Reg Anesth Pain Med* 2007; **32**: 130–5
- 10 Bodner G, Bernathova M, Galiano K, Putz D, Martinoli C, Felfernig M. Ultrasound of the lateral femoral cutaneous nerve: normal findings in a cadaver and in volunteers. *Reg Anesth Pain Med* 2009; **34**: 265–8
- 11 Bruhn J, Van Geffen GJ, Gielen MJ, Scheffer GJ. Visualization of the course of the sciatic nerve in adult volunteers by ultrasonography. *Acta Anaesthesiol Scand* 2008; **52**: 1298–302
- 12 Carney J, McDonnell JG, Ochana A, Bhinder R, Laffey JG. The transversus abdominis plane block provides effective postoperative analgesia in patients undergoing total abdominal hysterectomy. *Anesth Analg* 2008; **107**: 2056–60
- 13 Chan VW, Nova H, Abbas S, McCartney CJ, Perlas A, Xu DQ. Ultrasound examination and localization of the sciatic nerve: a volunteer study. *Anesthesiology* 2006; **104**: 309–14
- 14 Chan VW, Perlas A, McCartney CJ, Brull R, Xu D, Abbas S. Ultrasound guidance improves success rate of axillary brachial plexus block. *Can J Anaesth* 2007; **54**: 176–82
- 15 Christophe JL, Berthier F, Boillot A, et al. Assessment of topographic brachial plexus nerves variations at the axilla using ultrasonography. *Br J Anaesth* 2009; **103**: 606–12
- 16 Clendenen SR, Riutort K, Ladlie BL, Robards C, Franco CD, Greengrass RA. Real-time three-dimensional ultrasound-assisted axillary plexus block defines soft tissue planes. *Anesth Analg* 2009; **108**: 1347–50
- 17 Collins AB, Gray AT, Kessler J. Ultrasound-guided supraclavicular brachial plexus block: a modified Plumb-Bob technique. *Reg Anesth Pain Med* 2006; **31**: 591–2
- 18 Desgagnes MC, Levesque S, Dion N, et al. A comparison of a single or triple injection technique for ultrasound-guided infraclavicular block: a prospective randomized controlled study. *Anesth Analg* 2009; **109**: 668–72
- 19 Dingemans E, Williams SR, Arcand G, et al. Neurostimulation in ultrasound-guided infraclavicular block: a prospective randomized trial. *Anesth Analg* 2007; **104**: 1275–80
- 20 Dolan J, Williams A, Murney E, Smith M, Kenny GN. Ultrasound guided fascia iliaca block: a comparison with the loss of resistance technique. *Reg Anesth Pain Med* 2008; **33**: 526–31
- 21 Duggan E, Brull R, Lai J, Abbas S. Ultrasound-guided brachial plexus block in a patient with multiple glomangiomatosis. *Reg Anesth Pain Med* 2008; **33**: 70–3
- 22 Duggan E, El Beheiry H, Perlas A, et al. Minimum effective volume of local anesthetic for ultrasound-guided supraclavicular brachial plexus block. *Reg Anesth Pain Med* 2009; **34**: 215–8
- 23 Eichenberger U, Greher M, Kirchmair L, Curatolo M, Moriggl B. Ultrasound-guided blocks of the ilioinguinal and iliohypogastric nerve: accuracy of a selective new technique confirmed by anatomical dissection. *Br J Anaesth* 2006; **97**: 238–43
- 24 El-Dawlatly AA, Turkistani A, Kettner SC, et al. Ultrasound-guided transversus abdominis plane block: description of a new technique and comparison with conventional systemic analgesia during laparoscopic cholecystectomy. *Br J Anaesth* 2009; **102**: 763–7
- 25 Erickson JM, Louis DS, Naughton NN. Symptomatic phrenic nerve palsy after supraclavicular block in an obese man. *Orthopedics* 2009; **32**: 368
- 26 Fredrickson M. 'Oblique' needle-probe alignment to facilitate ultrasound-guided femoral catheter placement. *Reg Anesth Pain Med* 2008; **33**: 383–4
- 27 Fredrickson MJ, Patel A, Young S, Chinchawala S. Speed of onset of 'corner pocket supraclavicular' and infraclavicular ultrasound guided brachial plexus block: a randomised observer-blinded comparison. *Anaesthesia* 2009; **64**: 738–44
- 28 Guttman OT, Soffer RJ, Rosenblatt MA. The ultrasound-guided supraclavicular-interscalene (UGSCIS) block: a case report. *Pain Pract* 2008; **8**: 62–4
- 29 Handoll HH, Koscielniak-Nielsen ZJ. Single, double or multiple injection techniques for axillary brachial plexus block for hand, wrist or forearm surgery. *Cochrane Database Syst Rev* 2006; CD003842
- 30 Hara K, Sakura S, Nomura T. Use of ultrasound for thoracic paravertebral block. *Masui* 2007; **56**: 925–31
- 31 Hara K, Sakura S, Nomura T, Saito Y. Ultrasound guided thoracic paravertebral block in breast surgery. *Anaesthesia* 2009; **64**: 223–5
- 32 Hebbard P. Subcostal transversus abdominis plane block under ultrasound guidance. *Anesth Analg* 2008; **106**: 674–5
- 33 Helayel PE, da Conceicao DB, Pavei P, Knaesel JA, de Oliveira Filho GR. Ultrasound-guided obturator nerve block: a preliminary report of a case series. *Reg Anesth Pain Med* 2007; **32**: 221–6
- 34 Hurdle MF, Weingarten TN, Crisostomo RA, Psimos C, Smith J. Ultrasound-guided blockade of the lateral femoral cutaneous nerve: technical description and review of 10 cases. *Arch Phys Med Rehabil* 2007; **88**: 1362–4
- 35 Kapral S, Greher M, Huber G, et al. Ultrasonographic guidance improves the success rate of interscalene brachial plexus blockade. *Reg Anesth Pain Med* 2008; **33**: 253–8
- 36 Karmakar MK, Ho AM, Li X, Kwok WH, Tsang K, Ngan Kee WD. Ultrasound-guided lumbar plexus block through the acoustic window of the lumbar ultrasound trident. *Br J Anaesth* 2008; **100**: 533–7
- 37 Karmakar MK, Kwok WH, Ho AM, Tsang K, Chui PT, Gin T. Ultrasound-guided sciatic nerve block: description of a new approach at the subgluteal space. *Br J Anaesth* 2007; **98**: 390–5
- 38 Karmakar MK, Li X, Ho AM, Kwok WH, Chui PT. Real-time ultrasound-guided paramedian epidural access: evaluation of a novel in-plane technique. *Br J Anaesth* 2009; **102**: 845–54
- 39 Kato N, Fujiwara Y, Harato M, et al. Serum concentration of lidocaine after transversus abdominis plane block. *J Anesth* 2009; **23**: 298–300
- 40 Kessler J, Schaffhalter-Zoppoth I, Gray AT. An ultrasound study of the phrenic nerve in the posterior cervical triangle: implications for the interscalene brachial plexus block. *Reg Anesth Pain Med* 2008; **33**: 545–50
- 41 Koscielniak-Nielsen ZJ, Frederiksen BS, Rasmussen H, Hesselbjerg L. A comparison of ultrasound-guided supraclavicular and infraclavicular blocks for upper extremity surgery. *Acta Anaesthesiol Scand* 2009; **53**: 620–6
- 42 Krombach J, Gray AT. Sonography for saphenous nerve block near the adductor canal. *Reg Anesth Pain Med* 2007; **32**: 369–70

- 43 Levesque S, Dion N, Desgagne MC. Endpoint for successful, ultrasound-guided infraclavicular brachial plexus block. *Can J Anaesth* 2008; **55**: 308
- 44 Lundblad M, Kapral S, Marhofer P, Lonnqvist PA. Ultrasound-guided infrapatellar nerve block in human volunteers: description of a novel technique. *Br J Anaesth* 2006; **97**: 710–4
- 45 Luyet C, Eichenberger U, Greif R, Vogt A, Szucs Farkas Z, Moriggl B. Ultrasound-guided paravertebral puncture and placement of catheters in human cadavers: an imaging study. *Br J Anaesth* 2009; **102**: 534–9
- 46 Marhofer P, Bosenberg A, Sitzwohl C, Willschke H, Wanzel O, Kapral S. Pilot study of neuraxial imaging by ultrasound in infants and children. *Paediatr Anaesth* 2005; **15**: 671–6
- 47 Mariano ER, Afra R, Loland VJ, et al. Continuous interscalene brachial plexus block via an ultrasound-guided posterior approach: a randomized, triple-masked, placebo-controlled study. *Anesth Analg* 2009; **108**: 1688–94
- 48 Mariano ER, Loland VJ, Ilfeld BM. Interscalene perineural catheter placement using an ultrasound-guided posterior approach. *Reg Anesth Pain Med* 2009; **34**: 60–3
- 49 McDonnell JG, Curley G, Carney J, et al. The analgesic efficacy of transversus abdominis plane block after cesarean delivery: a randomized controlled trial. *Anesth Analg* 2008; **106**: 186–91
- 50 McDonnell JG, O'Donnell B, Curley G, Heffernan A, Power C, Laffey JG. The analgesic efficacy of transversus abdominis plane block after abdominal surgery: a prospective randomized controlled trial. *Anesth Analg* 2007; **104**: 193–7
- 51 Meier G, Bauereis C, Heinrich C. Interscalene brachial plexus catheter for anesthesia and postoperative pain therapy. Experience with a modified technique. *Anaesthesist* 1997; **46**: 715–9
- 52 Meier G, Bauereis C, Maurer H, Meier T. Interscalene plexus block. Anatomic requirements—anesthesiologic and operative aspects. *Anaesthesist* 2001; **50**: 333–41
- 53 Moayeri N, Bigeleisen PE, Groen GJ. Quantitative architecture of the brachial plexus and surrounding compartments, and their possible significance for plexus blocks. *Anesthesiology* 2008; **108**: 299–304
- 54 Morimoto M, Popovic J, Kim JT, Kiamzon H, Rosenberg AD. Case series: septa can influence local anesthetic spread during infraclavicular brachial plexus blocks. *Can J Anaesth* 2007; **54**: 1006–10
- 55 Ng I, Vaghadia H, Choi PT, Helmy N. Ultrasound imaging accurately identifies the lateral femoral cutaneous nerve. *Anesth Analg* 2008; **107**: 1070–4
- 56 Niazi AU, Prasad A, Ramlogan R, Chan VW. Methods to ease placement of stimulating catheters during in-plane ultrasound-guided femoral nerve block. *Reg Anesth Pain Med* 2009; **34**: 380–1
- 57 Niraj G, Searle A, Mathews M, et al. Analgesic efficacy of ultrasound-guided transversus abdominis plane block in patients undergoing open appendectomy. *Br J Anaesth* 2009; **103**: 601–5
- 58 O'Donnell BD, Mannion S. A case of liver trauma with a blunt regional anesthesia needle while performing transversus abdominis plane block. *Reg Anesth Pain Med* 2009; **34**: 75–6
- 59 O'Donnell BD, McDonnell JG, McShane AJ. The transversus abdominis plane (TAP) block in open retropubic prostatectomy. *Reg Anesth Pain Med* 2006; **31**: 91
- 60 Perlas A, Lobo G, Lo N, Brull R, Chan VW, Karkhanis R. Ultrasound-guided supraclavicular block: outcome of 510 consecutive cases. *Reg Anesth Pain Med* 2009; **34**: 171–6
- 61 Plunkett AR, Brown DS, Rogers JM, Buckenmaier CC, 3rd. Supraclavicular continuous peripheral nerve block in a wounded soldier: when ultrasound is the only option. *Br J Anaesth* 2006; **97**: 715–7
- 62 Pusch F, Wildling E, Klimscha W, Weinstabl C. Sonographic measurement of the needle insertion depth in paravertebral blocks in women. *Br J Anaesth* 2000; **85**: 841–3
- 63 Redborg KE, Antonakakis JG, Beach ML, Chinn CD, Sites BD. Ultrasound improves the success rate of a tibial nerve block at the ankle. *Reg Anesth Pain Med* 2009; **34**: 256–60
- 64 Redborg KE, Sites BD, Chinn CD, et al. Ultrasound improves the success rate of a sural nerve block at the ankle. *Reg Anesth Pain Med* 2009; **34**: 24–8
- 65 Robards C, Clendenen S, Greengrass R. Intravascular injection during ultrasound-guided axillary block: negative aspiration can be misleading. *Anesth Analg* 2008; **107**: 1754–5
- 66 Saranteas T. Limitations in ultrasound imaging techniques in anesthesia: obesity and muscle atrophy? *Anesth Analg* 2009; **109**: 993–4
- 67 Saranteas T, Anagnostopoulou S, Chantzi C. Obturator nerve anatomy and ultrasound imaging. *Reg Anesth Pain Med* 2007; **32**: 539–40
- 68 Schwemmer U, Markus CK, Greim CA, Brederlau J, Kredel M, Roewer N. Sonographic imaging of the sciatic nerve division in the popliteal fossa. *Ultraschall Med* 2005; **26**: 496–500
- 69 Schwemmer U, Markus CK, Greim CA, Brederlau J, Roewer N. Ultrasound-guided anaesthesia of the axillary brachial plexus: efficacy of multiple injection approach. *Ultraschall Med* 2005; **26**: 114–9
- 70 Shibata Y, Sato Y, Fujiwara Y, Komatsu T. Transversus abdominis plane block. *Anesth Analg* 2007; **105**: 883
- 71 Shorthouse JR, Danbury CM. Ultrasound-guided supraclavicular brachial plexus block in Klippel–Feil syndrome. *Anaesthesia* 2009; **64**: 693–4
- 72 Sinha SK, Abrams JH, Houle TT, Weller RS. Ultrasound-guided obturator nerve block: an interfascial injection approach without nerve stimulation. *Reg Anesth Pain Med* 2009; **34**: 261–4
- 73 Sites BD, Beach ML, Spence BC, et al. Ultrasound guidance improves the success rate of a perivascular axillary plexus block. *Acta Anaesthesiol Scand* 2006; **50**: 678–84
- 74 Soares LG, Brull R, Chan VW. Teaching an old block a new trick: ultrasound-guided posterior tibial nerve block. *Acta Anaesthesiol Scand* 2008; **52**: 446–7
- 75 Soares LG, Brull R, Lai J, Chan VW. Eight ball, corner pocket: the optimal needle position for ultrasound-guided supraclavicular block. *Reg Anesth Pain Med* 2007; **32**: 94–5
- 76 Soong J, Schaffhalter-Zoppoth I, Gray AT. Sonographic imaging of the obturator nerve for regional block. *Reg Anesth Pain Med* 2007; **32**: 146–51
- 77 Stone MB, Price DD, Wang R. Ultrasound-guided supraclavicular block for the treatment of upper extremity fractures, dislocations, and abscesses in the ED. *Am J Emerg Med* 2007; **25**: 472–5
- 78 Stone MB, Wang R, Price DD. Ultrasound-guided supraclavicular brachial plexus nerve block vs procedural sedation for the treatment of upper extremity emergencies. *Am J Emerg Med* 2008; **26**: 706–10
- 79 Tran TM, Ivanusic JJ, Hebbard P, Barrington MJ. Determination of spread of injectate after ultrasound-guided transversus abdominis plane block: a cadaveric study. *Br J Anaesth* 2009; **102**: 123–7
- 80 Tran de QH, Charghi R, Finlayson RJ. The 'double bubble' sign for successful infraclavicular brachial plexus blockade. *Anesth Analg* 2006; **103**: 1048–9
- 81 Tsui BC, Doyle K, Chu K, Pillay J, Dillane D. Case series: ultrasound-guided supraclavicular block using a curvilinear probe in 104 day-case hand surgery patients. *Can J Anaesth* 2009; **56**: 46–51

- 82 Tsui BC, Twomey C, Finucane BT. Visualization of the brachial plexus in the supraclavicular region using a curved ultrasound probe with a sterile transparent dressing. *Reg Anesth Pain Med* 2006; **31**: 182–4
- 83 Tumber PS, Bhatia A, Chan VW. Ultrasound-guided lateral femoral cutaneous nerve block for meralgia paresthetica. *Anesth Analg* 2008; **106**: 1021–2
- 84 VadeBoncouer TR, Weinberg GL, Oswald S, Angelov F. Early detection of intravascular injection during ultrasound-guided supraclavicular brachial plexus block. *Reg Anesth Pain Med* 2008; **33**: 278–9
- 85 van Geffen GJ, Rettig HC, Koornwinder T, Renes S, Gielen MJ. Ultrasound-guided training in the performance of brachial plexus block by the posterior approach: an observational study. *Anaesthesia* 2007; **62**: 1024–8
- 86 Walter EJ, Smith P, Albertyn R, Uncles DR. Ultrasound imaging for transversus abdominis blocks. *Anaesthesia* 2008; **63**: 211
- 87 Willschke H, Bosenberg A, Marhofer P, et al. Ultrasonographic-guided ilioinguinal/iliohypogastric nerve block in pediatric anaesthesia: what is the optimal volume? *Anesth Analg* 2006; **102**: 1680–4
- 88 Willschke H, Bosenberg A, Marhofer P, et al. Epidural catheter placement in neonates: sonoanatomy and feasibility of ultrasonographic guidance in term and preterm neonates. *Reg Anesth Pain Med* 2007; **32**: 34–40
- 89 Willschke H, Marhofer P, Bosenberg A, et al. Ultrasonography for ilioinguinal/iliohypogastric nerve blocks in children. *Br J Anaesth* 2005; **95**: 226–30
- 90 Willschke H, Marhofer P, Bosenberg A, et al. Epidural catheter placement in children: comparing a novel approach using ultrasound guidance and a standard loss-of-resistance technique. *Br J Anaesth* 2006; **97**: 200–7
- 91 Zetlaoui PJ, Labbe JP, Benhamou D. Ultrasound guidance for axillary plexus block does not prevent intravascular injection. *Anesthesiology* 2008; **108**: 761